

*Neutrophil-mediated erythrophagocytosis following Russell's viper (*Daboia russelii*) bite*

Article

Published Version

Creative Commons: Attribution 4.0 (CC-BY)

Open Access

Senthilkumaran, S., Arathisenthil, S. V., Williams, J., Almeida, J. R., Williams, H. F., Rajan, E., Thirumalaikolundusubramanian, P., Patel, K. and Vaiyapuri, S. ORCID: <https://orcid.org/0000-0002-6006-6517> (2023) Neutrophil-mediated erythrophagocytosis following Russell's viper (*Daboia russelii*) bite. *Toxicon*, 228. 107111. ISSN 0041-0101 doi: <https://doi.org/10.1016/j.toxicon.2023.107111> Available at <https://centaur.reading.ac.uk/111517/>

It is advisable to refer to the publisher's version if you intend to cite from the work. See [Guidance on citing](#).

To link to this article DOI: <http://dx.doi.org/10.1016/j.toxicon.2023.107111>

Publisher: Elsevier


All outputs in CentAUR are protected by Intellectual Property Rights law, including copyright law. Copyright and IPR is retained by the creators or other copyright holders. Terms and conditions for use of this material are defined in the [End User Agreement](#).

www.reading.ac.uk/centaur

CentAUR

Central Archive at the University of Reading

Reading's research outputs online



Case report

Neutrophil-mediated erythrophagocytosis following Russell's viper (*Daboia russelii*) bite

Subramanian Senthilkumaran^{a,1}, S.V. Arathisenthil^{a,1}, Jarred Williams^{b,1}, José R. Almeida^{b,1}, Harry F. Williams^c, Elanchezhian Rajan^b, Ponniah Thirumalaikolundusubramanian^d, Ketan Patel^e, Sakthivel Vaiyapuri^{b,*}

^a Manian Medical Centre, Erode, 638001, Tamil Nadu, India

^b School of Pharmacy, University of Reading, Reading, RG6 6UB, UK

^c Toxiven Biotech Private Limited, Coimbatore, 641042, Tamil Nadu, India

^d The Tamil Nadu Dr M.G.R Medical University, Chennai, 600032, Tamil Nadu, India

^e School of Biological Sciences, University of Reading, RG6 6UB, UK



ARTICLE INFO

Handling Editor: Ray Norton

Keywords:

Snakebite envenomation
Russell's viper
Daboia russelii
Erythrophagocytosis
Neutrophils
Peripheral blood smear

ABSTRACT

Snakebite envenomation is regarded as a high-priority neglected tropical disease by the World Health Organisation, as it results in significant loss of lives and permanent disabilities. Russell's viper is one of the important venomous snakes that causes morbidities, mortalities and disabilities in India. The clinical presentation of Russell's viper envenomation is characterised by local envenoming effects including tissue damage, venom-induced coagulopathy, neurotoxicity, and kidney injury. However, venom composition and its mechanisms of toxicity are highly variable even within snakes of the same species including Russell's viper. This variation in venom composition results in a broad range of clinical complications. Here, we present a previously undocumented case of neutrophil-mediated erythrophagocytosis in a healthy 28-year-old female following Russell's viper bite. Systemic envenomation effects and bleeding abnormalities in this patient were corrected by the administration of polyvalent antivenom. Two days later, the patient developed progressive swelling and ecchymosis in the bitten limb. Observed abnormal limits within blood testing were followed up by a peripheral blood smear where it was found that 30% of neutrophils had phagocytosed erythrocytes as they were found within the cytoplasm. The patient underwent a fasciotomy for compartmental syndrome and received packed red cells and a course of corticosteroids. Following this treatment, the patient made a full recovery. This case report outlines a previously undocumented pathological event induced by Russell's viper envenomation, guiding diagnosis and treatment. Clinicians' knowledge of the mechanisms of toxicity of Russell's viper envenomation and its clinical manifestations are essential for improving the treatment of snakebites to achieve positive outcomes.

1. Introduction

Snakebite envenomation (SBE) has been regarded as a high-priority neglected tropical disease by the World Health Organisation (Chippaux, 2017). There are between 1.8 and 2.7 million people affected by SBE annually, resulting in an estimated 138,000 deaths and 500,00 permanent disabilities (Gutiérrez, 2021). India is the epicentre of SBE with an estimated 58,000 deaths each year, and poor rural agricultural workers are the most at risk (Suraweera et al., 2020). Russell's viper (*Daboia*

russelii) is responsible for roughly 45% of all envenomation in India (Vaiyapuri et al., 2013; Suraweera et al., 2020; Samuel et al., 2021). Typical clinical manifestations of Russell's viper envenomation include neurotoxicity, venom-induced consumption coagulopathy (VICC), and tissue damage. However, a range of other/rare pathological manifestations has been reported in several victims following Russell's viper bites (Senthilkumaran et al., 2021a, 2021b, 2022a, 2022b; Arathisenthil et al., 2022). Clinical knowledge of rare SBE manifestations is essential for rapid diagnosis and treatment to mitigate the disastrous

* Corresponding author.

E-mail address: s.vaiyapuri@reading.ac.uk (S. Vaiyapuri).

¹ These authors contributed equally to this study.

consequences of SBE toxicities.

Neutrophils are a key component of innate immunity, and they are the first inflammatory cells to be recruited at the damaged tissue or respond to invading pathogens in the blood. Once at the site of damage, they combat microbial infiltration, phagocytose necrotic cells, and release inflammatory mediators that regulate inflammation and promote the regeneration of tissues (Liew and Kubes, 2019; Zuliani et al., 2020). The large size of neutrophils (around 15–20 μm) facilitates their phagocytic actions, and they have the ability to regulate both pro- and anti-inflammatory responses. Erythrophagocytosis is an understudied clinical manifestation characterised by specific morphological features and alterations on peripheral blood smears suggesting the clearance of red blood cells by the most abundant type of granulocytes (i.e., neutrophils) (Lee, 2017). As described previously, it is not commonly observed within the peripheral blood of healthy humans but is linked to haemolytic conditions such as haemolytic anaemia, paroxysmal cold haemoglobinuria, and incompatible blood transfusions (Bain, 2006; Lewandowski et al., 2011). Other erythrophagocytosis cases associated with different aetiologies include sickle cell anaemia, clonal malignancies and poisoning with potassium chlorate (Eichener, 1984; Lewandowski et al., 2011; Lee, 2017). In this study, we report a previously undocumented Russell's viper bite-induced neutrophil-mediated erythrophagocytosis in a healthy SBE victim.

2. Case report

A 28-year-old healthy female from a rural area in South India was bitten by a snake on her left ankle while harvesting grass. Her past medical history was unremarkable. According to the patient, she had not taken any medications, surgical interventions, or blood transfusions and had not been exposed to any toxic substances or infections. She was first taken to a local hospital within 1 h of the bite and received 100 mL (10 vials) of polyvalent antivenom, to normalise the coagulation abnormalities (prolonged 20-min whole blood clotting time). She did not present any other noticeable clinical manifestations at this stage. The

offending snake was killed and presented to a qualified herpetologist, who identified it as Russell's viper (Fig. 1A). Her systemic envenomation effects improved following the antivenom administration, and the haematological, biochemical, and metabolic values were within normal limits at this point (6 hours after the bite). Therefore, no other parameters including blood smear were not examined. There were no further signs of envenomation on day 2 (until 48 hours after the bite). However, on day 3, she developed progressive swelling and ecchymosis (brushing) of the bitten limb, and she complained of severe weakness, dizziness, nausea, and vomiting. She was, therefore, referred to the emergency department of our hospital 72 hours after the bite. On arrival, she was pale, conscious, well-oriented, moderately built, and well-nourished with yellowish sclera (white region of the eyes). Her supine blood pressure was 80/40 mmHg, pulse 126 bpm which was normal, temperature 36.5 °C, and pulse oximetry 93% in room air. Auscultation revealed normal heart sounds without any murmur or gallop and the lungs were clear. The examinations of her abdomen and the central nervous system did not reveal any abnormalities. Local examination revealed that the left leg was markedly swollen with ecchymosis around the bite site (Fig. 1B).

Laboratory examinations of the patient upon admission in our hospital are summarised in Table 1. These results revealed an elevated white cell count with significantly increased neutrophils, and reduced haematocrit and haemoglobin levels. Moreover, total and direct bilirubin, lactate dehydrogenase, alanine aminotransferase, aspartate aminotransferase and creatinine levels were all increased. However, decreased haptoglobin level was observed. All other parameters did not reveal any abnormalities and the values were within normal limits.

A peripheral blood smear showed nearly 30% (as calculated by phagocytic index = number of phagocytosed cells/total number of neutrophils in microscopic images \times 100) of neutrophils phagocytosed erythrocytes as demonstrated by their presence in the cytoplasm (Fig. 1C–E). Monocytes were not involved. Direct and indirect Coombs's test, cold agglutinins, a methyl-violet preparation for Heinz bodies, and flow-cytometric immunophenotyping for paroxysmal nocturnal

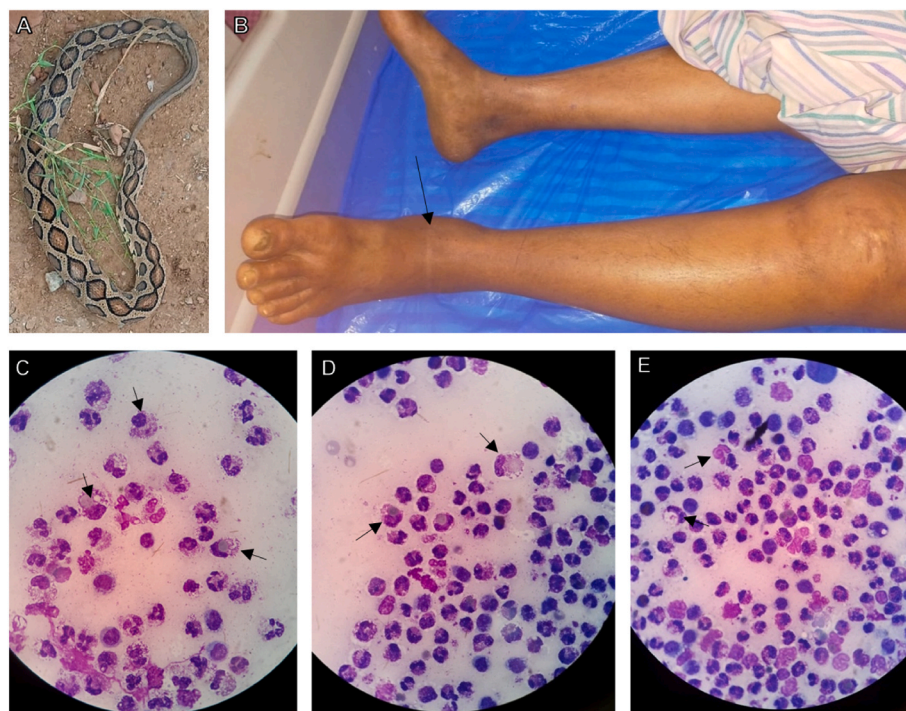


Fig. 1. Neutrophil-mediated erythrophagocytosis in a patient following Russell's viper bite. (A) The protagonist snake was identified as Russell's viper by a trained herpetologist. (B) The patient's legs, with signs of swelling around the bite site on the left ankle (indicated with an arrow). (C–E) Microscopic images of haematoxylin & eosin-stained peripheral blood smear showing erythrophagocytosis by neutrophils as they were found within the cytoplasm of neutrophils (indicated with arrows).

Table 1
Laboratory findings of the patient upon admission to our hospital.

Clinical parameters	Results	Units	Normal range
Total WBC count	12.73	$\times 10^9$ cells/L	4.0–11.0
Neutrophils	85	%	
HCT	22.2	%	36.8–46.0
Haemoglobin	5.8	g/dL	12.0–14.0
Bilirubin (total)	4.2	mg/dL	0.2–1.2
Bilirubin (direct)	1.9	mg/dL	<0.5
Lactate dehydrogenase	856	U/L	134–279
Alanine aminotransferase	65	U/L	0–35
Aspartate aminotransferase	76	U/L	5–35
Creatinine	1.6	mg/dL	0.6–1.1
Haptoglobin	0.06	g/L	0.3–2.0
Platelet Count	155	$\times 10^9$ Cells/L	140–400
Mean corpuscular volume	74.8	fL	79–98
Reticulocytes	2.66	%	0.5–2.0
Alkaline phosphatase	94	U/L	40–150
Fibrinogen	218	mg/dL	200–400
INR	1.45	Ratio	0.8–1.2
aPTT	30.5	Seconds	26–39
D-dimers	3.6	mg/L	<5

WBC, white blood cells; HCT, haematocrit; INR, international normalised ratio of clotting; aPTT, activated partial thromboplastin time.

haemoglobinuria were negative. The results of haemoglobin electrophoresis, G6PD, osmotic fragility test of erythrocytes and pyruvic kinase levels, and vitamin B12, folate, and ferritin levels were within normal ranges. Immune antibodies directed against erythrocytes were not detected. Serum immunological tests did not detect antinuclear, anti-granulocytic antibodies, or cryoglobulins. Hepatitis B and C, human immunodeficiency virus, active Epstein-Barr virus, *Pneumocystis jiroveci* and *Borrelia* infections were not detected. The abdominal ultrasound showed no abnormalities.

She required a fasciotomy to tackle the compartmental syndrome and was transfused with two units of packed red blood cells. She was started on methylprednisolone 500 mg intravenously twice daily for 5 days, and her haemoglobin concentration increased to 10.8 g/dL (after 48 hours of the last dose of methylprednisolone), and plasma concentrations of bilirubin and lactate dehydrogenase came down to normal ranges. The patient was discharged on day 10 (from admission to our hospital). Her peripheral smear was normal during a follow-up assessment 30 days after the bite. She did not present any other complications during the regular weekly follow-up assessments of up to six months. The fasciotomy-associated wound healed completely within the first two weeks and then no further complications observed.

3. Discussion

Russell's viper envenomation has a broad range of clinical manifestations. While most of the complications have been well documented, the rare manifestations such as priapism, parotid swelling, rectus sheath haematoma, bilateral adrenal and pituitary haemorrhages and others, still require further documentation and investigation (Pothukuchi et al., 2018; Senthilkumaran et al., 2021a, 2021b, 2022a, 2022b, 2023a, 2023b; Arathisenthil et al., 2022; Ganguly et al., 2022). Robust knowledge of the clinical manifestations of SBE is essential for prompt diagnosis and treating complications as they arise. Moreover, reports of rare clinical manifestations are key learning tools for clinicians and the scientific communities to be able to draw on experience, raise awareness and ensure appropriate treatment regimens are delivered for a positive patient outcome.

Many components of snake venoms are known to interact with the immune system, triggering the release of proinflammatory mediators and modulating cell signalling. Moreover, some venom toxins are known to disrupt the extracellular matrix in the vasculature and local tissues (Herkert et al., 2001; Pareja-Santos et al., 2009; Avalo et al., 2022). Phospholipase A₂s (PLA₂), common components found within viperid

venoms induce the production of eicosanoids, which are neutrophil chemoattractants that work to resolve acute inflammatory response at the site of injury (Leiguez et al., 2014; Moreira et al., 2016). L-amino acid oxidases have been reported to induce the production of reactive oxygen species, and stimulate neutrophils to release proinflammatory mediators, which subsequently promote their migration to the site of damage to ingest particles by phagocytosis (Witko-Sarsat et al., 2000; Pontes et al., 2014). Other venom components can directly affect the haemostatic system, inducing local and systemic haemorrhage through disruption of the vascular cell lining, inhibition or activation of clotting factors, inhibition of platelet activation and erythrocyte lysis through the destruction of their plasma membrane (Matsui et al., 2000; Lu et al., 2005; Sajevic et al., 2011; Slagboom et al., 2017). Two earlier studies, including an *in vitro* evaluation and a clinical presentation, described the effects of venoms on erythrocytes. The first investigation assessed the osmotic fragility of human red blood cells incubated with *Vipera lebetina* venom (Mohammad et al., 2014). The second study presents three case reports of snakebite victims who displayed microangiopathic haemolytic anaemia (Namal Rathnayaka et al., 2018). In viperid venoms, indirect erythrocyte lysis is induced through hydrolysis of the phospholipid cell membrane by PLA₂ (De Vries et al., 1962; Condrea et al., 1964). An acidic PLA₂, RVVA-PLA₂-I isolated from the venom of Russell's viper preferentially hydrolyses the phospholipids of erythrocyte membranes due to the significant number of RVVA-PLA₂-I sensitive regions within the membrane (Saikia et al., 2012).

Erythrophagocytosis is important for the turnover of red blood cells, and this process commonly occurs within the spleen (Mebius and Kraal, 2005; Meinderts et al., 2017). Red blood cells are viable for roughly 110–120 days, and as the cells age and they become senescent, signals on the surface of the cell trigger phagocytosis by macrophages (de Back et al., 2014). Auto-antibody formation against red blood cells can occur in autoimmune haemolytic conditions, and subsequent immunoglobulin G (IgG) opsonization of red blood cells will promote phagocytosis by neutrophils. The rate of neutrophil-mediated erythrophagocytosis is dependent on the level of IgG opsonization and this process is negatively controlled by the inhibitory CD47-SIRP α pathway (Burger et al., 2012). Moreover, this process can be potentiated by various inflammatory mediators (Meinderts et al., 2017).

The only scientifically validated treatment for SBE is antivenom (Laloo and Theakston, 2003; Warrell, 2017). Antivenoms are preparations of whole IgG or antibody F (ab'2) fragments collected from the serum of animals that have been immunised with one or multiple snake venoms (Laloo and Theakston, 2003; León et al., 2007). Several adverse effects have been observed in patients receiving antivenom treatment. The incidence rate and severity of these reactions vary greatly (Cardoso et al., 1993; Otero et al., 1999; Laloo and Theakston, 2003). Symptomatology of these adverse reactions generally includes urticaria, itching, nausea, vomiting, colic, fever, hypotension, and bronchospasms (Otero et al., 1999; León et al., 2007). Antibodies that react with human erythrocytes have been identified in equine serum and within equine-derived antivenoms. These antibodies bind to human erythrocytes and induce agglutination (Levinson and Miller, 2002; León et al., 2007). Such antibodies do not induce direct haemolysis but they might be responsible for erythrophagocytosis by cells of the mononuclear phagocyte system (Kessary-Shoham et al., 1999).

Localised swelling around the bite site is common following SBE, however, the extent of the swelling and ecchymosis in this patient led clinicians to perform a peripheral blood smear. The results of the peripheral blood smear highlighted erythrophagocytosis by around 30% of neutrophils. It was apparent that RED blood cells were engulfed by neutrophils. Immunosuppressive drug therapy has been used successfully in treating this rare condition characterised by neutrophils ingesting red blood cells in an SBE victim. The implementation of this therapeutic approach induced a reduction in the activity of the body's immune system and contributed to a favourable outcome in this patient. This new case report expands the literature on the diversity of symptoms

associated with Russell's viper bites-induced toxicity in humans and encourages researchers to decipher the mechanisms behind this event and its treatment. The study of the role and functional aspects of Russell's viper venom components and a more detailed analysis of the antivenom interaction with blood cells may help to understand this rare phenomenon. While the causes of neutrophil-mediated erythrophagocytosis in SBE victims are hypothetical, awareness is key to the successful clinical management of SBE. Once again, we emphasise that the spectrum of symptoms goes beyond the classic generalisation commonly used to classify and identify Russell's viper envenomation. Therefore, more awareness about such rare conditions following bites from Russell's viper and other snakes is critical among healthcare professionals in order to tackle these issues promptly to achieve positive patient outcomes.

Credit author statement

Subramanian Senthilkumaran: Conceptualization, Methodology, Validation, Investigation, Resources, Data Curation, Visualization and Supervision. **S.V. Arathisenthil:** Methodology, Validation, Investigation, Data Curation and Visualization. **Jarred Williams:** Formal analysis, Writing - Original Draft, Writing - Review & Editing, and Visualization. **José R. Almeida:** Formal analysis, Writing - Original Draft, Writing - Review & Editing, and Visualization. **Harry F. Williams:** Formal analysis, Methodology, and Writing - Review & Editing. **Elanchezian Rajan:** Formal analysis, Writing - Original Draft, and Visualization. **Ponniiah Thirumalaikolundusubramanian:** Conceptualization, Methodology, Validation, Formal analysis, and Writing - Review & Editing. **Ketan Patel:** Formal analysis, Resources, and Writing - Review & Editing. **Sakthivel Vaiyapuri:** Conceptualization, Methodology, Formal analysis, Validation, Investigation, Resources, Data Curation, Writing - Original Draft, Writing - Review & Editing, Visualization, and Supervision.

Ethical statement

This study was performed in line with the Declaration of Helsinki, and permitted by the Institutional Ethics Committee of Toxiven Biotech Private Limited (2019–001/002 on the October 11, 2019). Written informed consent was obtained from the patient to collect and publish this data.

Declaration of competing interest

The authors declare that they have no known competing financial interests or personal relationships that could have appeared to influence the work reported in this paper.

Data availability

No data was used for the research described in the article.

Acknowledgements

We would like to thank the Medical Research Council, UK for their funding support (grant reference: MR/W019353/1 and ITP PhD studentship).

References

Arathisenthil, S.V., Senthilkumaran, S., Vijayakumar, P., Savania, R., Williams, H.F., Elangovan, N., Bicknell, A.B., Patel, K., Trim, S.A., Thirumalaikolundusubramanian, P., Vaiyapuri, S., 2022. Rapid development of a salivary calculus in submandibular gland and its potential causes in a young victim following Russell's viper bite. *Toxicol* 206, 85–89.

Avalo, Z., Barrera, M.C., Agudelo-Delgado, M., Tobón, G.J., Cañas, C.A., 2022. Biological effects of animal venoms on the human immune system. *Toxins* 14.

Bain, B., 2006. *J-blood Cells: a Practical Guide*, fourth ed. Blackwell publishing, Massachusetts, EUA.

Burger, P., Hilarius-Stokman, P., de Korte, D., van den Berg, T.K., van Bruggen, R., 2012. CD47 functions as a molecular switch for erythrocyte phagocytosis. *Blood* 119, 5512–5521.

Cardoso, J.L., Fan, H.W., França, F.O., Jorge, M.T., Leite, R.P., Nishioka, S.A., Avila, A., Sano-Martins, I.S., Tomy, S.C., Santoro, M.L., et al., 1993. Randomized comparative trial of three antivenoms in the treatment of envenoming by lance-headed vipers (*Bothrops jararaca*) in São Paulo, Brazil. *Q. J. Med.* 86, 315–325.

Chippaux, J.P., 2017. Snakebite envenomation turns again into a neglected tropical disease. *J. Venom. Anim. Toxins Incl. Trop. Dis.* 23, 38.

Condrea, E., Mammon, Z., Aloof, S., de Vries, A., 1964. Susceptibility of erythrocytes of various animal species to the hemolytic and phospholipid splitting action of snake venom. *Biochim. Biophys. Acta (BBA) - Spec. Sect. Lipids Relat. Subj.* 84, 365–375.

de Back, D., Kostova, E., van Kraaij, M., van den Berg, T., Van Bruggen, R., 2014. Of macrophages and red blood cells; a complex love story. *Front. Physiol.* 5.

De Vries, A., Kirschmann, C., Klibansky, C., Condrea, E., Gitter, S., 1962. Hemolytic action of indirect lytic snake venom in vivo. *Toxicol* 1, 19–23.

Eichener, E.R., 1984. Spider bite hemolytic anemia: positive Coombs test, erythrophagocytosis and leukoerythroblastic smear. *Am. J. Clin. Pathol.* 81, 683–687.

Ganguly, D., Ghosh, S., Dutta, S., Chandra, A., 2022. Bilateral parotid swelling in viper bite: further evidence for a poor prognosis. *BMJ Case Rep.* 15, e252217.

Gutiérrez, J.M., 2021. Snakebite Envenomation as a Neglected Tropical Disease: New Impetus for Confronting an Old Scourge, *Handbook of Venoms and Toxins of Reptiles*. CRC Press, pp. 471–484.

Herkert, M., Shakhman, O., Schweins, E., Becker, C.-M., 2001. β -Bungarotoxin is a potent inducer of apoptosis in cultured rat neurons by receptor-mediated internalization. *Eur. J. Neurosci.* 14, 821–828.

Kessary-Shoham, H., Levy, Y., Shoenfeld, Y., Lorber, M., Gershon, H., 1999. In vivo administration of intravenous immunoglobulin (IVIg) can lead to enhanced erythrocyte sequestration. *J. Autoimmun.* 13, 129–135.

Laloo, D.G., Theakston, R.D., 2003. Snake antivenoms. *J. Toxicol. Clin. Toxicol.* 41, 277–290, 317–227.

Lee, J.H., 2017. A rare case of erythrophagocytosis by neutrophils on the peripheral blood smear. *Blood Res.* 52, 74–75.

Leiguez, E., Giannotti, K.C., Moreira, V., Matsubara, M.H., Gutiérrez, J.M., Lomonte, B., Rodríguez, J.P., Balsinde, J., Teixeira, C., 2014. Critical role of TLR2 and MyD88 for functional response of macrophages to a group IIA-secreted phospholipase A₂ from snake venom. *PLoS One* 9, e93741.

León, G., Rodríguez, M.A., Rucavado, A., Lomonte, B., Gutiérrez, J.M., 2007. Anti-human erythrocyte antibodies in horse-derived antivenoms used in the treatment of snakebite envenomations. *Biologicals* 35, 5–11.

Levinson, S.S., Miller, J.J., 2002. Towards a better understanding of heterophile (and the like) antibody interference with modern immunoassays. *Clin. Chim. Acta* 325, 1–15.

Lewandowski, K., Homenda, W., Mital, A., Complak, A., Hellmann, A., 2011. Erythrophagocytosis by neutrophils – a rare morphological phenomenon resulting in acquired haemolytic anaemia? *Int. J. Lab. Hematol.* 33, 447–450.

Liew, P.X., Kubes, P., 2019. The neutrophil's role during health and disease. *Physiol. Rev.* 99, 1223–1248.

Lu, Q., Clemetson, J.M., Clemetson, K.J., 2005. Snake venoms and hemostasis. *J. Thromb. Haemostasis* 3, 1791–1799.

Matsui, T., Fujimura, Y., Titani, K., 2000. Snake venom proteases affecting hemostasis and thrombolysis. *Biochim. Biophys. Acta Protein Struct. Mol. Enzymol.* 1477, 146–156.

Mebius, R.E., Kraal, G., 2005. Structure and function of the spleen. *Nat. Rev. Immunol.* 5, 606–616.

Meinderts, S.M., Oldenburg, P.A., Beuger, B.M., Klei, T.R.L., Johansson, J., Kuijpers, T. W., Matozaki, T., Huisman, E.J., de Haas, M., van den Berg, T.K., van Bruggen, R., 2017. Human and murine splenic neutrophils are potent phagocytes of IgG-opsonized red blood cells. *Blood Adv.* 1, 875–886.

Mohammad, M.A., Talafih, K., Al-rob, O.Y.A., Gharaibeh, N.S., Ayeshe, M., 2014. Osmotic fragility of human erythrocytes in vitro using *Vipera lebetina* venom. *Comp. Clin. Pathol.* 23, 249–254.

Moreira, V., Teixeira, C., Borges da Silva, H., D'Império Lima, M.R., Dos-Santos, M.C., 2016. The role of TLR2 in the acute inflammatory response induced by *Bothrops atrox* snake venom. *Toxicol* 118, 121–128.

Namal Rathnayaka, R.M.M.K., Ranathunga, A.N., Kularatne, S.A.M., Rajapakse, J., Ranasinghe, S., Jayathunga, R., 2018. Microangiopathic hemolytic anemia following three different species of hump-nosed pit viper (genus: hypnale) envenoming in Sri Lanka. *Wilderness Environ. Med.* 29 (1), 94–101.

Otero, R., Gutiérrez, J.M., Rojas, G., Núñez, V., Díaz, A., Miranda, E., Uribe, A.F., Silva, J. F., Ospina, J.G., Medina, Y., Toro, M.F., García, M.E., León, G., García, M., Lizano, S., De La Torre, J., Márquez, J., Mena, Y., González, N., Arenas, L.C., Puzón, A., Blanco, N., Sierra, A., Espinal, M.E., Lozano, R., et al., 1999. A randomized blinded clinical trial of two antivenoms, prepared by caprylic acid or ammonium sulphate fractionation of IgG, in *Bothrops* and *Porthidium* snake bites in Colombia: correlation between safety and biochemical characteristics of antivenoms. *Toxicol* 37, 895–908.

Pareja-Santos, A., Saraiva, T.C., Costa, E.P., Santos, M.F., Zorn, T.T., Souza, V.M., Lopes-Ferreira, M., Lima, C., 2009. Delayed local inflammatory response induced by *Thalassophryne nattereri* venom is related to extracellular matrix degradation. *Int. J. Exp. Pathol.* 90, 34–43.

Pontes, A.S., da, S.S.S., Xavier, C.V., Lacouth-Silva, F., Kayano, A.M., Pires, W.L., Nery, N.M., Boeri de Castro, O., da Silva, S.D., Calderon, L.A., Stábili, R.G., Soares, A.M., Zuliani, J.P., 2014. Effect of L-amino acid oxidase from *Calloselasma rhodostoma* snake venom on human neutrophils. *Toxicol* 80, 27–37.

- Pothukuchi, V., Chepuri, V., Natta, K., Madigani, N., Kumar, A., 2018. A rare case report of Russell's viper snakebite with ischemic stroke. *Hong Kong J. Emerg. Med.* 25, 95–97.
- Saikia, D., Bordoloi, N.K., Chattopadhyay, P., Choklingam, S., Ghosh, S.S., Mukherjee, A. K., 2012. Differential mode of attack on membrane phospholipids by an acidic phospholipase A₂ (RVVA-PLA2-I) from *Daboia russelli* venom. *Biochim. Biophys. Acta Biomembr.* 1818, 3149–3157.
- Sajevic, T., Leonardi, A., Krizaj, I., 2011. Haemostatically active proteins in snake venoms. *Toxicon* 57, 627–645.
- Samuel, S.P., Chinnaraju, S., Williams, H.F., Pichamuthu, E., Subharao, M., Vaiyapuri, M., Arumugam, S., Vaiyapuri, R., Baksh, M.F., Patel, K., Trim, S.A., Duncombe, T.E., Vaiyapuri, S., 2021. Venomous snakebites: rapid action saves lives—a multifaceted community education programme increases awareness about snakes and snakebites among the rural population of Tamil Nadu, India. *PLoS Neglected Trop. Dis.* 14, e0008911.
- Senthilkumaran, S., Vijayakumar, P., Savania, R., Vaiyapuri, R., Elangovan, N., Patel, K., Trim, S.A., Thirumalaikolundusubramanian, P., Vaiyapuri, S., 2021a. Splenic rupture and subsequent splenectomy in a young healthy victim following Russell's viper bite. *Toxicon* 204, 9–13.
- Senthilkumaran, S., Williams, H.F., Patel, K., Trim, S.A., Thirumalaikolundusubramanian, P., Vaiyapuri, S., 2021b. Priapism following a juvenile Russell's viper bite: an unusual case report. *PLoS Neglected Trop. Dis.* 15, e0009242.
- Senthilkumaran, S., Miller, S.W., Williams, H.F., Savania, R., Thirumalaikolundusubramanian, P., Patel, K., Vaiyapuri, S., 2022a. Development of Wunderlich syndrome following a Russell's viper bite. *Toxicon* 215, 11–16.
- Senthilkumaran, S., Miller, S.W., Williams, H.F., Vaiyapuri, R., Savania, R., Elangovan, N., Thirumalaikolundusubramanian, P., Patel, K., Vaiyapuri, S., 2022b. Ultrasound-guided compression method effectively counteracts Russell's viper bite-Induced pseudoaneurysm. *Toxins*.
- Senthilkumaran, S., Almeida, J.R., Williams, J., Salim, A., Williams, H.F., Thirumalaikolundusubramanian, P., Patel, K., Vaiyapuri, S., 2023a. Russell's viper envenomation induces rectus sheath haematoma. *Toxicon* 224, 107037.
- Senthilkumaran, S., Almeida, J.R., Williams, J., Williams, H.F., Thirumalaikolundusubramanian, P., Patel, K., Vaiyapuri, S., 2023b. Rapid identification of bilateral adrenal and pituitary haemorrhages induced by Russell's viper envenomation results in positive patient outcome. *Toxicon* 15 (225), 107068.
- Slagboom, J., Kool, J., Harrison, R.A., Casewell, N.R., 2017. Haemotoxic snake venoms: their functional activity, impact on snakebite victims and pharmaceutical promise. *Br. J. Haematol.* 177, 947–959.
- Suraweera, W., Warrell, D., Whitaker, R., Menon, G., Rodrigues, R., Fu, S.H., Begum, R., Sati, P., Piyasena, K., Bhatia, M., Brown, P., Jha, P., 2020. Trends in snakebite deaths in India from 2000 to 2019 in a nationally representative mortality study. *Elife* 9, e54076.
- Vaiyapuri, S., Vaiyapuri, R., Ashokan, R., Ramasamy, K., Nattamaisundar, K., Jeyaraj, A., Chandran, V., Gajjeraman, P., Baksh, M.F., Gibbins, J.M., Hutchinson, E.G., 2013. Snakebite and its socio-economic impact on the rural population of Tamil Nadu, India. *PLoS One* 8, e80090.
- Warrell, D.A., 2017. Clinical toxicology of snakebite in Africa and the Middle East/Arabian Peninsula. In: *Handbook of Clinical Toxicology of Animal Venoms and Poisons*. CRC Press, pp. 433–492.
- Witko-Sarsat, V., Rieu, P., Descamps-Latscha, B., Lesavre, P., Halbwachs-Mecarelli, L., 2000. Neutrophils: molecules, functions and pathophysiological aspects. *Lab. Invest.* 80, 617–653.
- Zuliani, J.P., Soares, A.M., Gutiérrez, J.M., 2020. Polymorphonuclear neutrophil leukocytes in snakebite envenoming. *Toxicon* 187, 188–197.